

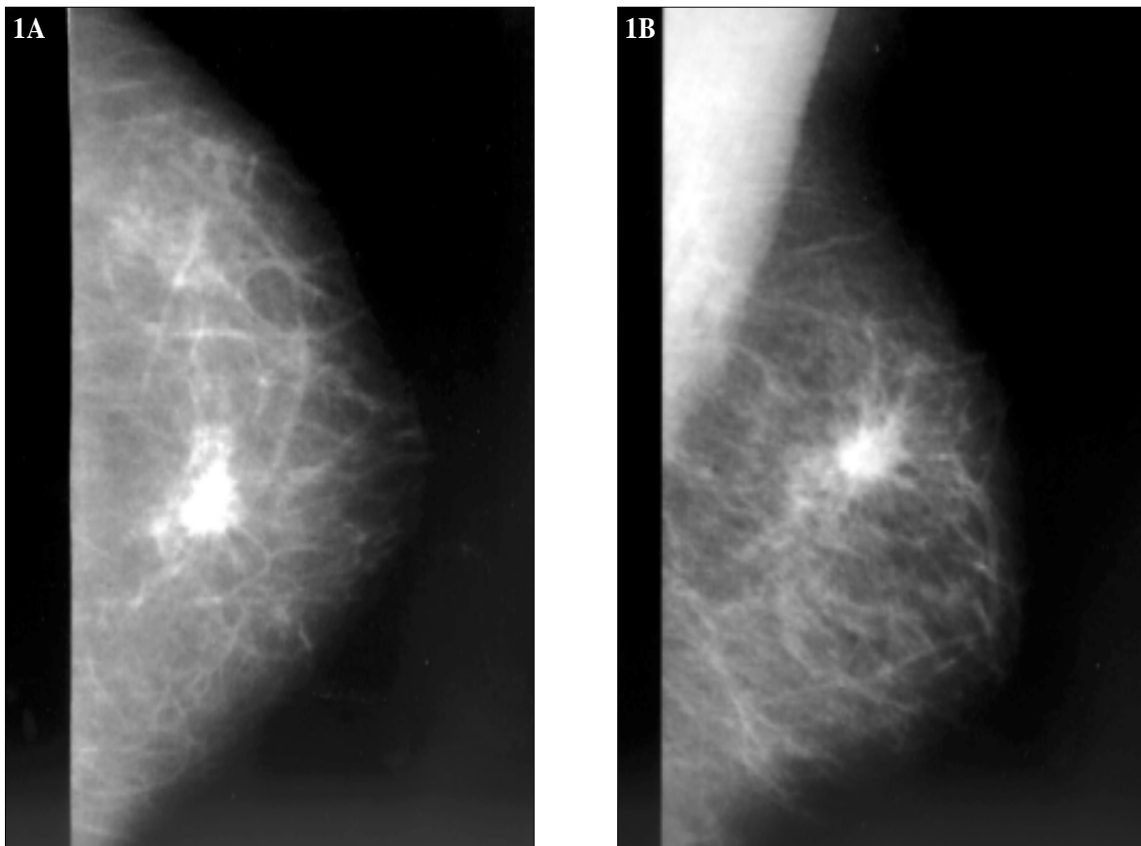
Incidental breast mass

M Muttarak, B Chaiwun

Clinical history:

A 66-year-old woman was referred for routine screening mammography. Standard craniocaudal (**Figure 1A**) and mediolateral oblique (**Figure 1B**) mammograms of the left breast were performed.

Figures 1A & 1B: Craniocaudal (A), mediolateral oblique (B) mammograms of the left breast



What is your diagnosis?

- a) Fibroadenoma
- b) Cyst
- c) Hamartoma
- d) Carcinoma
- e) Haematoma

*See page 32
for the answer*