

Solitary pulmonary mass

B K Choudhury, W C G Peh 白振源

Clinical history:

A 57 years old man presented with cough and haemoptysis. Chest radiographs showed a rounded right lung mass (not shown). An enhanced computed tomography (CT) of the thorax was done. (Figures 1 & 2)

Figure 1: Enhanced CT scan of the thorax (lung window) taken at the level of the carina

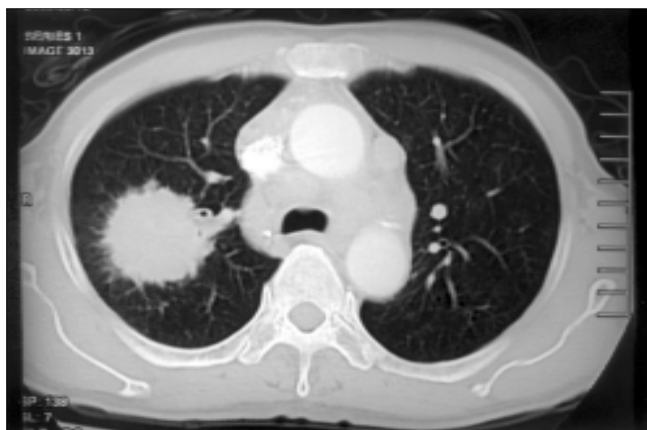
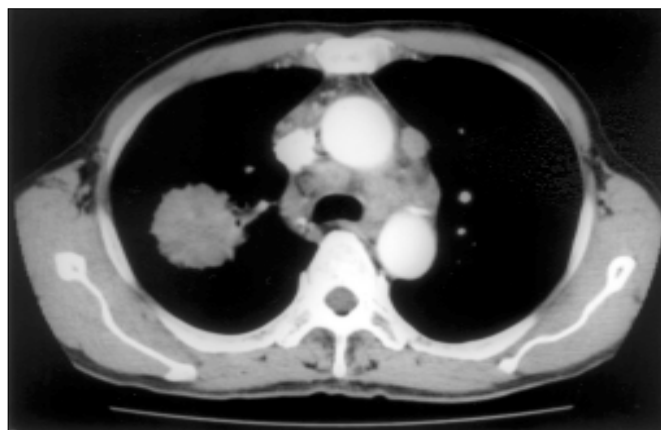


Figure 2: Enhanced CT scan of the thorax (mediastinal window) taken at the level of the carina



What is the diagnosis?

- a) Malignant mesothelioma
- b) Hamartoma
- c) Bronchogenic carcinoma
- d) Pulmonary metastasis
- e) Pulmonary arteriovenous malformation (AVM)

*See page 270
for the answer*