

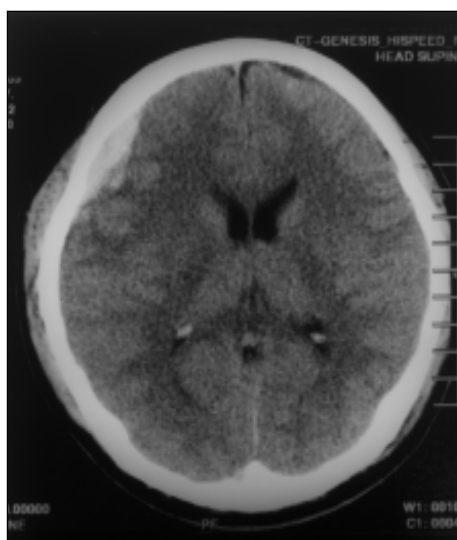
Acute head injury

B K Choudhury, W C G Peh 白振源

Clinical history:

A 21 years old man sustained loss of consciousness following head injury during a road traffic accident. Non-contrast computed tomography (CT) scanning of the head was performed. (**Figure 1**)

Figure 1: Non-contrast CT scan of the head (brain window)



What is the diagnosis?

- a) Subdural haematoma
- b) Subarachnoid haemorrhage
- c) Intracerebral haemorrhage
- d) Epidural haemorrhage
- e) Haemorrhagic infarction

*See page 409
for the answer*